

See discussions, stats, and author profiles for this publication at: <https://www.researchgate.net/publication/26657041>

Vertical Ridge Augmentation Using Guided Bone Regeneration (GBR) in Three Clinical Scenarios Prior to Implant Placement: A Retrospective Study of 35 Patients 12 to 72 Months After...

Article in *The International journal of oral & maxillofacial implants* · May 2009

Source: PubMed

CITATIONS

229

READS

8,216

3 authors, including:



Istvan Urban

University of Michigan

90 PUBLICATIONS 3,260 CITATIONS

[SEE PROFILE](#)



Jaime Lozada

Loma Linda University

131 PUBLICATIONS 6,638 CITATIONS

[SEE PROFILE](#)

Vertical Ridge Augmentation Using Guided Bone Regeneration (GBR) in Three Clinical Scenarios Prior to Implant Placement: A Retrospective Study of 35 Patients 12 to 72 Months After Loading

Istvan A. Urban, DMD, MD¹/Sascha A. Jovanovic, DDS, MS²/Jaime L. Lozada, DDS³

Purpose: The aims of the current study were to: (1) evaluate the results of vertical guided bone regeneration (GBR) with particulate autogenous bone grafts, (2) determine clinically and radiographically the success and survival rates of 82 implants placed in such surgical sites after prosthetic loading for 12 to 72 months, and (3) compare defects that were treated simultaneously with sinus augmentation and vertical GBR to other areas of the jaw treated with vertical GBR only. **Materials and Methods:** Eighty-two implants were inserted in 35 patients with 36 three-dimensional vertical bone defects. The patients were divided into three groups: single missing teeth (group A), multiple missing teeth (group B), and vertical defects in the posterior maxilla only (group C). All group C subjects were treated simultaneously with sinus and vertical augmentations. All patients were treated with vertical ridge augmentation utilizing titanium-reinforced polytetrafluoroethylene (e-PTFE) membranes and particulated autografts. After removal of the e-PTFE membrane, all sites received a collagen membrane. **Results:** At membrane removal, mean vertical augmentation was 5.5 mm (\pm 2.29 mm). Mean combined crestal remodeling was 1.01 mm (\pm 0.57 mm) at 12 months, which remained stable through the 6-year follow-up period. There were no statistically significant differences between the three groups in mean marginal bone remodeling. One defect had a bone graft complication (2.78%, 95% CI: 0.00%, 8.15%). The overall implant survival rate was 100% with a cumulative success rate of 94.7%. **Conclusions:** (1) Vertical augmentation with e-PTFE membranes and particulated autografts is a safe and predictable treatment; (2) success and survival rates of implants placed in vertically augmented bone with the GBR technique appear similar to implants placed in native bone under loading conditions; (3) success and failure rates of implants placed into bone regenerated simultaneously with sinus and vertical augmentation techniques compare favorably to those requiring only vertical augmentation. *INT J ORAL MAXILLOFAC IMPLANTS* 2009;24:502–510

Key words: autogenous bone graft, barrier membranes, guided bone regeneration, sinus augmentation, vertical ridge augmentation

Vertical and horizontal augmentation using guided bone regeneration (GBR) has become a major treatment option to provide optimal bone support

for osseointegrated dental implants. The application of GBR for horizontal augmentation is well documented, with high rates of implant success and low complication rates.^{1–4} The application of GBR for supracrestal regeneration was introduced and the surgical technique described in 1998,⁵ and the first animal and human histologic studies demonstrated successful vertical bone augmentation.^{6,7} Complications reported with vertical augmentation have involved membrane exposure and/or subsequent infection, with rates ranging between 12.5% and 17%.^{5,7,8} The long-term results of vertical GBR following 1 to 5 years of prosthetic loading were examined in a retrospective multicenter study evaluating 123 implants⁹; vertical bone regeneration of more than 4 mm was achieved only with the use of autogenous bone chips. These authors reported an overall success rate of 97.5%, leading them to conclude that bone

¹Assistant Professor, Graduate Implant Dentistry, Loma Linda University, Loma Linda, California; Private Practice in Periodontics and Implant Dentistry, Budapest, Hungary.

²Lecturer, Continuing Dental Education, University of California Los Angeles (UCLA), Los Angeles, California.

³Professor, Department of Restorative Dentistry, Director of Graduate Implant Dentistry, Loma Linda University, Loma Linda, California.

Correspondence to: Dr Istvan Urban, Sodras utca 9, Budapest, Hungary 1026. Fax: +36-12004447. Email: istvan@implant.hu

Preliminary results were presented in 2004 at the annual meeting of the European Association of Osseointegration in Paris, France.

that has been vertically augmented using GBR techniques responds to implant placement in a fashion similar to native bone. In another study, the GBR technique for vertical augmentation was used in combination with a sinus lift procedure for posterior maxillary reconstruction.¹⁰ However, the implant survival and success rates were 92.1% and 76.3%, respectively, which conflicted with previously reported results on vertical and horizontal GBR.^{4,9} There are few reports of vertical GBR, and they present conflicting results and relatively high complication rates.

The aims of this retrospective study were to: (1) evaluate results of vertical GBR with particulated, autogenous bone grafts; (2) determine clinical and radiographic success and survival rates of implants placed in surgical sites after prosthetic loading; and (3) compare success and survival rates of implants placed in defects treated simultaneously with sinus augmentation and vertical GBR to other areas treated with vertical GBR only.

MATERIALS AND METHODS

This retrospective study reports on patients who were consecutively treated with vertical augmentation using GBR and particulated autografts from June 1999 to October 2004. All patients were treated at either the Center for Implant Dentistry, Loma Linda University School of Dentistry, Loma Linda, California, or in a private clinic in Budapest, Hungary. All surgical procedures were performed by the same clinician (I.U.), who had more than 15 years of experience in oral surgery and implant therapies, and the prosthetic treatments were performed by residents in the Loma Linda University Implant Dentistry program or private practitioners.

Patients were selected who required vertical bone regeneration (1) to achieve the necessary bone volume to place dental implants and (2) to improve the crown/implant ratio and esthetics. Patients were required to have good oral hygiene prior to treatment. Participants were excluded if they were current smokers, engaged in excessive alcohol consumption, or had uncontrolled systemic conditions or uncontrolled periodontal disease.

Clinical Procedures

All patients were treated with vertical ridge augmentation using titanium-reinforced, nonresorbable, expanded polytetrafluoroethylene (e-PTFE) membranes (GORE-TEX Regenerative Membrane, Titanium-Reinforced; W.L. Gore & Associates, Flagstaff, AZ) and particulated autografts. Defects were measured during the grafting procedures with a

calibrated periodontal probe. Vertical bone defects were measured from the most apical portion of the bony defect to a line connecting the interproximal bone between neighboring teeth or to the original bone crest of the edentulous area.

The surgical technique has been described previously.⁵ Briefly, a remote full-thickness flap was elevated in the edentulous area and the residual bone ridge was prepared carefully to receive an autogenous bone graft and an e-PTFE membrane. The autografts were harvested from the mandible, particulated in a bone mill (R. Quétin Bone-Mill, Roswitha Quétin Dental Products, Leimen, Germany), and applied to the defect. The bone graft was immobilized and covered with a membrane, which was stabilized with titanium bone tacks. When implants were placed simultaneously, the implants protruded from the base of the defect to the desired vertical position and were covered with the graft and membranes.

In posterior maxillary cases with both severe vertical crestal bone atrophy and enlarged maxillary sinus cavities, a combined procedure of vertical GBR and maxillary sinus grafting was used. The sinus grafts used the lateral window approach, and the grafting material consisted of autogenous particulated bone with anorganic bovine spongiosa bone mineral (Bio-Oss, Osteohealth, Shirley, NY). The classification and rationale for this procedure with posterior maxillary alveolar defects, which combines GBR and sinus bone grafts, have been described previously.^{10,11} Bone harvesting sites were selected based on the amount of bone required versus available bone and anatomic limitations. Clinical photographs were taken during the procedures (Fig 1).

The surgical site was allowed to heal for 6 to 9 months. Then, the membranes were removed, and implants were placed or uncovered. At the time of membrane removal, bone regeneration was evaluated. At implant placement, a resorbable collagen membrane (Bio-Gide, Osteohealth, Shirley, NY) was placed over the newly formed crestal bone to protect the graft from early resorption. The objective was to place the implant platform at the crestal bone level, leave it submerged to heal for 6 months, then uncover and restore the implants.

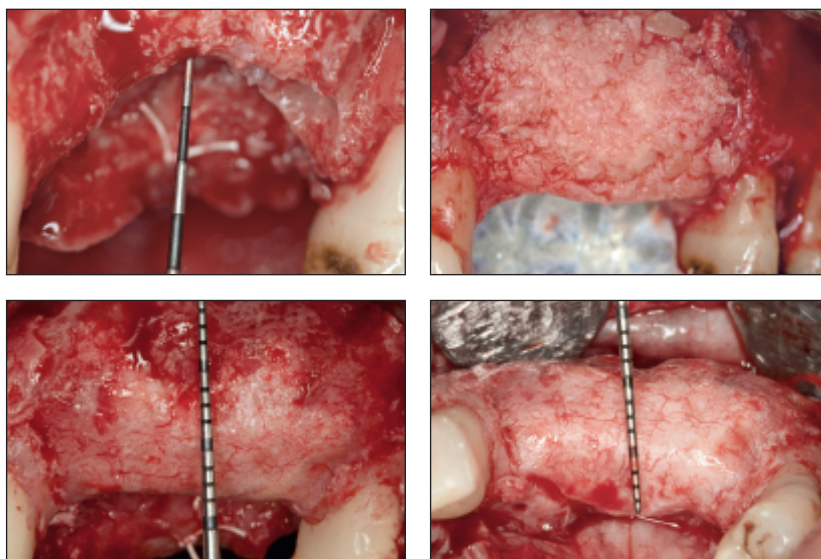
All patients were to receive a provisional prosthesis during the healing phase of the bone grafts and the implants to provide function and esthetics and avoid pressure on the operated site. Definitive restorations were placed within a few weeks after the implants were uncovered. Patients received fixed implant-supported restorations and attended a scheduled maintenance program that included a clinical examination every 6 months and annual radiographic examinations.

Fig 1 Measurement of a representative defect before and after treatment.

Fig 1a A 7-mm vertical defect involving three teeth.

Fig 1b Buccal view of the autogenous bone graft and membrane in place.

Figs 1c and 1d Regenerated bone crest at membrane removal after 9 months of healing.



Peri-implant mucosal conditions were assessed for redness, hyperplasia, suppuration, swelling, and the presence of plaque. Probing depths were recorded according to established methods.^{4,12,13} Periapical radiographs were obtained at abutment connection and then every 12 months thereafter with a long-cone paralleling technique. Crestal bone levels were measured to the nearest 0.01 mm using NIH Image software (National Institutes of Health, Bethesda, MD), with the implant-abutment junction as the baseline reference point.¹⁴ Complications in bone graft healing, such as membrane exposure and/or subsequent infection, were recorded.

Implant Success Criteria

Success was evaluated according to established methods. The absence of pain, foreign body sensation, dysesthesia, mobility, or peri-implant radiolucency were the clinical criteria for success throughout the follow-up period. Following the first year of function, there could be no more than 0.2 mm crestal bone remodeling annually,¹⁵ and ≤ 2.0 mm total crestal bone remodeling by the end of the fifth year was considered acceptable.¹⁶

Statistical Analysis

Recorded data were used for calculations of mean values and standard deviations (SDs). Cumulative success rates (CSRs) were evaluated using life table analysis.¹⁷ Significant differences in marginal bone level changes between the three groups were assessed by the *t* test, employing a critical *P* value of .0167 to account for multiple comparisons.

Table 1 Distribution and Surgical Approach in the Three Treatment Groups

Treatment group	No. of patients	No. of defects	No. of implants	Surgical approach (no. and %)	
				Simultaneous	Staged
A	12	12	12	4 (30.8)	9 (69.2)
B	16	16	42	2 (12.5)	14 (87.5)
C	7	8	28	0 (0.0)	8 (100.0)
Total	35	36	82	6	31

RESULTS

This retrospective study sought to encompass the scope of clinical practice where vertical bone augmentation is required for the purpose of implant placement: 82 implants were placed in 35 patients with 36 three-dimensional ridge defects ranging from 2 to 12 mm. Thirty-three patients (94.3%) were partially edentulous, and two (5.7%) were completely edentulous. Fourteen (40%) patients were men and 21 (60%) were women, and the mean age was 44.9 years (range, 19 to 72 years). A staged approach that allowed the graft to heal uneventfully before implant placement was used in most cases.

Table 1 provides treatment approaches of the patient sample. The patients treated with the simultaneous approach had less severe vertical defects, with a maximum defect size of 4 mm. With one exception, intraoral bone grafts were used; the graft was taken from the retromolar area in 21 cases (60%) and the chin in 13 cases (37.14%).¹⁸ In one patient (2.8%), bone was harvested from the hip.

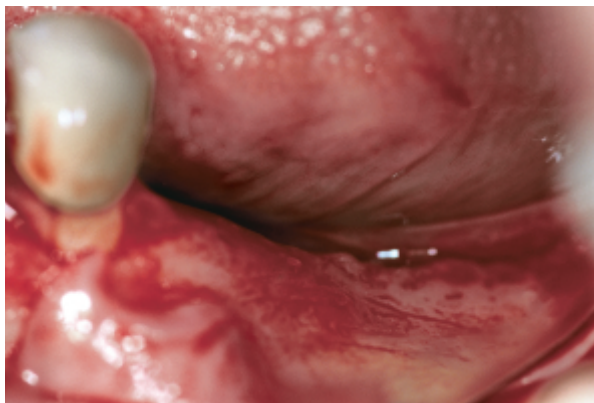

Fig 2a Atrophic posterior mandibular area in a representative case from treatment group B.

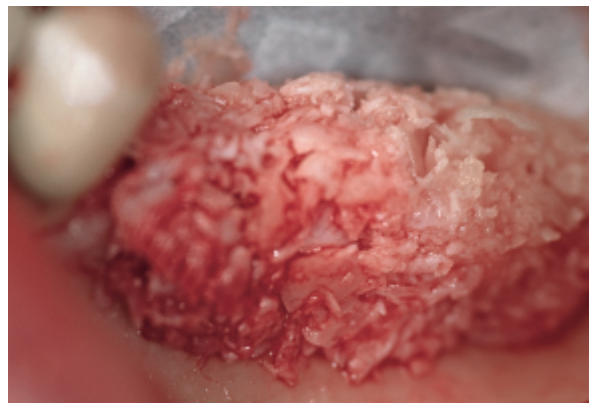


Fig 2b Particulated chin bone graft is placed on the ridge. The cortical bone was perforated, and the membrane was secured on the lingual side before applying bone graft.

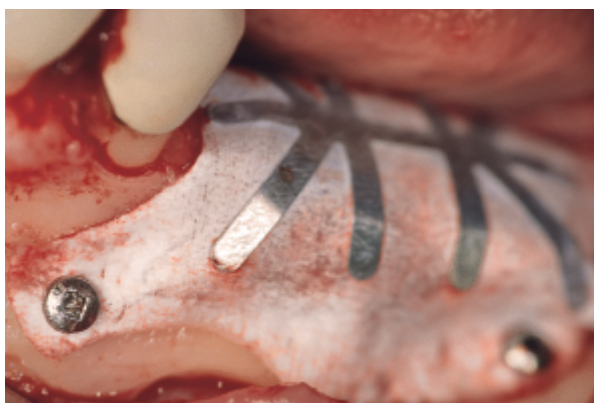

Fig 2c The membrane is secured over the graft with titanium pins.

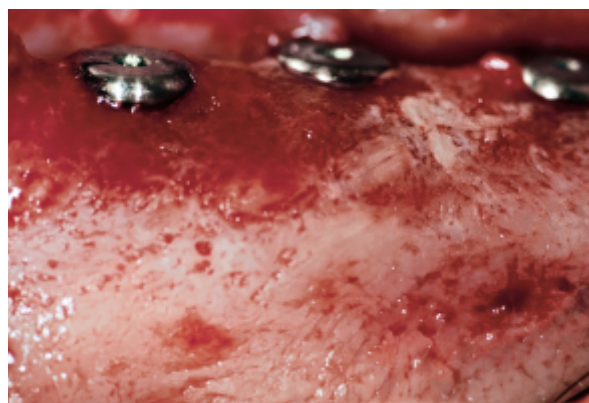


Fig 2d Three implants are in place in the newly formed posterior mandibular ridge. Note the well-integrated bone graft.

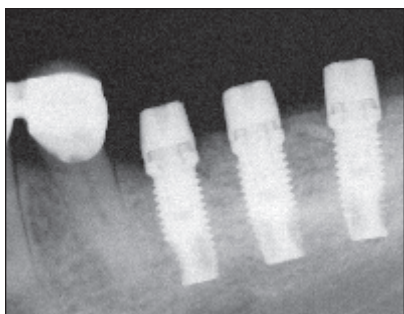


Fig 2e Periapical radiograph at abutment connection.

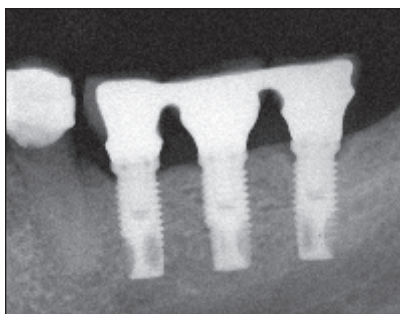


Fig 2f Periapical radiograph at 3-year follow-up with implant in function.

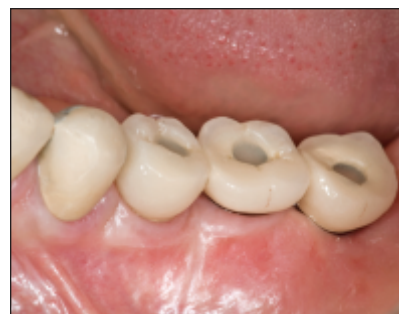

Fig 2g Clinical view demonstrates healthy peri-implant mucosa.

The implants used in this study were all commercially available from the same manufacturer at the time of the respective surgery. Thirteen acid-etched Steri-Oss (Nobel Biocare, Yorba Linda, CA), 66 anodized-surface Brånemark TiUnite (Nobel Biocare), and three anodized-surface Replace TiUnite (Nobel Biocare) implants were placed in the 35 patients. All

patients presented with vertical bone defects and were divided into three treatment groups: group A (12 patients) had single missing teeth, group B (16 patients) had multiple missing teeth, and group C (7 patients/8 defects) had vertical defects in the posterior maxilla only and were treated simultaneously with sinus and vertical augmentations.

Fig 3 Representative case requiring posterior maxillary bone regeneration (treatment group C).

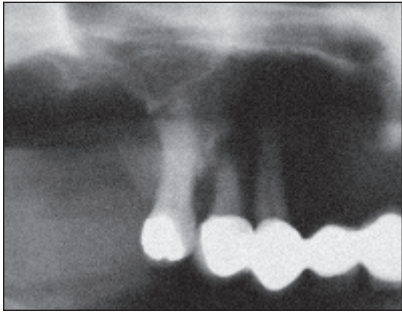


Fig 3a Vertical defect in the posterior maxilla.

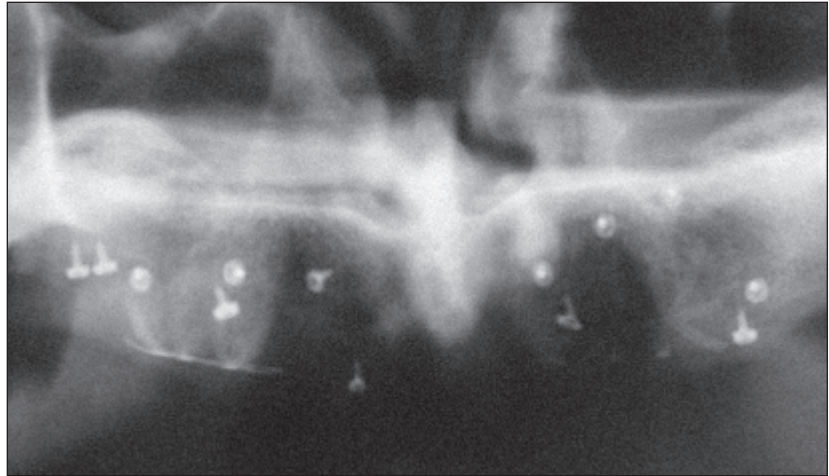
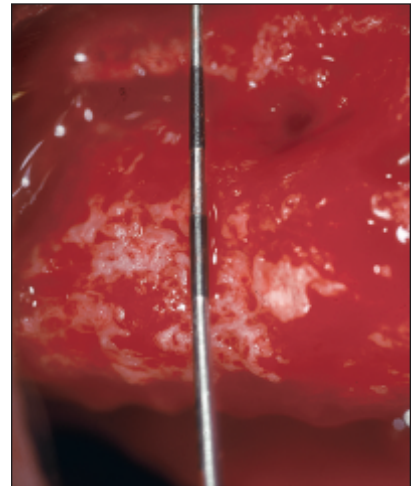
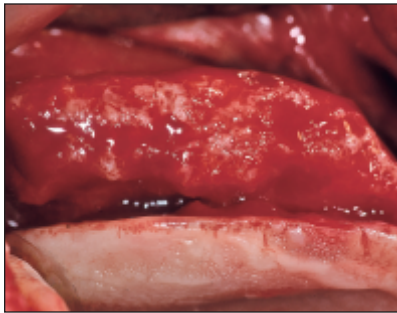


Fig 3b Panoramic radiograph shows defects after treatment with sinus augmentation and vertical GBR.



Figs 3c and 3d After 9 months of uneventful healing, complete vertical bone gain is demonstrated.

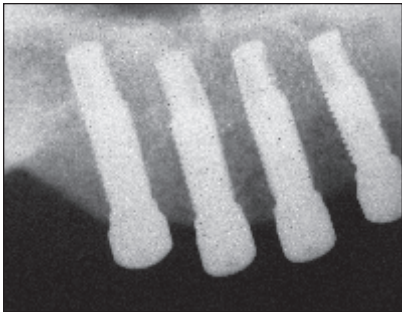


Fig 3e Radiograph of implants at abutment connection.

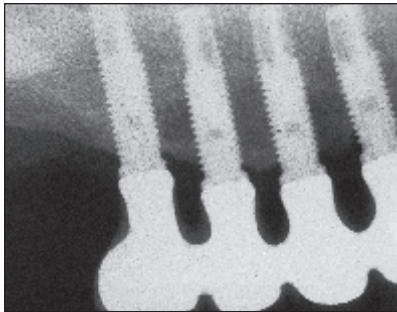


Fig 3f Radiograph of implants after 4 years of loading.

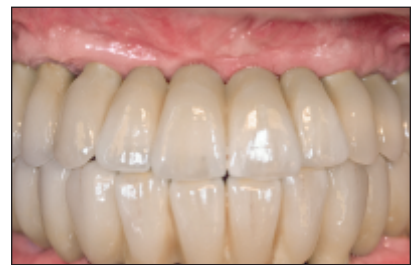

Fig 3g Definitive implant-supported complete fixed prosthesis.

Bone regeneration was evaluated clinically at the time of membrane removal. In general, all treated defect sites exhibited excellent bone formation, with an overall average of 5.5 mm (SD 2.29) of vertical augmentation (Table 2). None of the patients showed less bone regeneration than the space created by the membrane (Figs 2 and 3), with one exception.

Table 2 Results of Vertical Augmentation

Treatment group	Mean (mm)	SD (mm)	Range (mm)
A	4.7	1.67	3.0–9.0
B	5.1	2.13	2.0–8.0
C	7.4	2.56	4.0–12.0
Overall	5.5	2.29	2.0–12.0

Table 3 Mean Marginal Bone Loss Around Implants at Different Time Periods (In mm)

Time	Bone loss							
	Group A		Group B		Group C		Overall	
	Mean (SD)	n*	Mean (SD)	n*	Mean (SD)	n*	Mean (SD)	n*
Abutment connection	0.47 (0.61)	11	0.39 (0.47)	42	0.36 (0.58)	28	0.39 (0.53)	81
1 y	0.69 (0.55)	11	1.03 (0.53)	42	1.12 (0.58)	28	1.01 (0.57)	81
2 y	0.03 (0.17)	10	0.02 (0.32)	32	-0.15 (0.29)	25	-0.05 (0.28)	67
3 y	0.11 (0.22)	6	0.02 (0.2)	24	0.11 (0.1)	19	0.06 (0.18)	49
4 y	-0.08 (0.07)	3	-0.02 (0.14)	15	0.0 (0.14)	17	-0.02 (0.13)	35
5 y	-0.28	1	0.03 (0.1)	6	0.03 (0.12)	9	0.01 (0.13)	16
6 y			0.05 (0.0)	3	0.0 (0.12)	4	0.02 (0.1)	7

*No. of patients who attended the respective follow-up visit as a part of this retrospective study.

There was one complication associated with bone graft healing (2.78%, 95% CI: 0.00%, 8.15%). This group B patient developed a fistula on top of the membrane area 2 weeks after bone grafting. The surgical site was reopened and the membrane was removed carefully so that the graft was not disturbed. There was no visible infection of the graft. After gentle irrigation with saline, a resorbable collagen membrane (Bio-Gide) was placed over the graft, and the flap was closed and permitted to heal for an additional 7 months; at this point, implants were placed successfully. At the time of implant placement, 5 mm of the original vertical deficiency were still present, along with minimal vertical gain (2 mm).

Regardless of which site was used for bone harvesting, there appeared to be no difference in the results in terms of bone quality and quantity at implant placement or during the follow-up period when implants were assessed clinically and radiographically. Throughout the period of the study, no early or late resorption of the newly formed bone crest was noted. The use of collagen membranes at the time of implant placement was strictly empirical, and it was not possible to evaluate whether they were of any benefit in maintaining bone dimensions.

All implants were placed according to their predetermined optimal prosthetic positions. At the time of abutment connection, all implants were stable and were fully embedded within bone.

After the last exam for the cohort in this retrospective study, all patients had comfortable prostheses in place; all implants were still in function; and no patients reported any complaints of foreign body sensation, pain, or dysesthesia. Intraoral examinations demonstrated healthy peri-implant mucosa without suppuration, swelling, or redness at any implant sites. The mean probing depth was 3.03 mm (SD 0.61).

Two patients dropped out of the study after successful treatment. One patient in group A was lost to follow-up after the abutment connection, refused a

radiographic exam, and consequently could not be evaluated at the 1-year evaluation. The other patient was in group B and became lost to follow-up after the 1-year evaluation.

In the 81 consecutively treated implants that were evaluated clinically and radiographically after abutment connection, the period of functional loading in this study ranged from 1 to 6 years (mean: 40.3 months), and the mean radiographic follow-up was 34.2 months. At the 1-year examination, the mean crestal bone remodeling value for the 81 implants was 1.01 mm (SD 0.57) and, in most cases, the first bone-implant contact was located near the first implant thread. The mean marginal bone remodeling for the 81 implants throughout the study is provided in Table 3. There were no statistically significant differences between the three groups in mean marginal bone remodeling, and the crestal bone remained stable throughout the follow-up period.

All of the examined 81 implants survived (Tables 4 and 5). Only three implants in group B showed increased bone remodeling (slightly more than 2 mm), and these were not considered clinically successful.

DISCUSSION

Bone augmentation using GBR techniques is well documented and characterized by high predictability and survival of implants.^{4,19,20} However, few publications have reported long-term results on vertical ridge augmentation following GBR.^{9,10} These studies found that vertical bone regeneration of more than 4 mm could only be achieved with the use of autogenous bone chips. This is consistent with the present study, since up to 12 mm of vertical bone gain was achieved. None of the sites showed less bone regeneration than the space created by the membrane; however, the one site in which early membrane removal

Table 4 Life Table Analysis of Implants: Overall Cumulative Success Rates

Time	Implants			Cumulative success rate*	Standard error
	No. surveyed	No. of failures	No. censored		
Placement to loading	82	0	0	100.0%	0.0%
Loading to 1 y	82	0	1	100.0%	0.0%
1 y to 2 y	81	1 [†]	13	98.7%	1.3%
2 y to 3 y	67	1 ^{††}	17	97.0%	2.1%
3 y to 4 y	49	1 [§]	13	94.7%	3.1%
4 y to 5 y	35	0	19	94.7%	3.7%
5 y to 6 y	16	0	9	94.7%	5.5%
6 y to 7 y	7	0	7	94.7%	8.2%

*Based on implants that were evaluated in the respective follow-up period.

[†]Patient in group B who became lost to follow-up after the 1-year evaluation. One of the patient's two treated defects exhibited 2.5 mm of bone remodeling.

^{††}There was 2.2 mm of bone remodeling in one implant in group B.

[§]One implant in group B had 1.62 mm bone remodeling at the 1-year evaluation, and the amount of bone remodeling had increased to 2.38 mm at the 3-year evaluation.

Table 5 Life Table Analysis of Implants

Time	Implants			Cumulative success rate*	Standard error
	No. of implants	No. of failures	No. censored		
Placement to loading					
group A	12	0	0	100.0%	0.0%
group B	42	0	0	100.0%	0.0%
group C	28	0	0	100.0%	0.0%
Loading to 1 y					
group A	12	0	1	100.0%	0.0%
group B	42	0	0	100.0%	0.0%
group C	28	0	0	100.0%	0.0%
1 y to 2 y					
group A	11	0	1	100.0%	0.0%
group B	42	1	9	97.3%	2.5%
group C	28	0	3	100.0%	0.0%
2 y to 3 y					
group A	10	0	4	100.0%	0.0%
group B	32	1	7	93.9%	4.1%
group C	25	0	6	100.0%	0.0%
3 y to 4 y					
group A	6	0	3	100.0%	0.0%
group B	24	1	8	89.2%	6.0%
group C	19	0	2	100.0%	0.0%
4 y to 5 y					
group A	3	0	2	100.0%	0.0%
group B	15	0	9	89.2%	7.6%
group C	17	0	8	100.0%	0.0%
5 y to 6 y					
group A	1	0	1	100.0%	0.0%
group B	6	0	3	89.2%	12.0%
group C	9	0	5	100.0%	0.0%
6 y to 7 y					
group A	0	0	0	N/A	N/A
group B	3	0	3	89.2%	16.9%
group C	4	0	4	100.0%	0.0%

*Based on implants that had been evaluated in the respective follow-up period.

N/A = not applicable.

was necessary showed minimal (2 mm) vertical bone gain. This indicates that a dimensionally stable barrier, such as the titanium-reinforced e-PTFE membrane, may be necessary for vertical augmentation.

After abutment connection, clinical follow-up demonstrated healthy peri-implant mucosa and a mean probing depth of 3.03 mm. These values are consistent with those reported previously in long-term studies on implants placed into native^{13,21} and regenerated bone.^{4,9}

Crestal bone remodeling was measured from the implant-abutment junction. This showed an overall mean change of 1.01 mm in the first year and remained stable throughout the follow-up period. Similarly, 1.32 mm of remodeling was shown previously in a study reporting on 32 sites that were vertically augmented with autogenous bone chips and a titanium-reinforced e-PTFE membrane.⁹ In the current study, there was a slight difference in the first year between the three groups examined in this report. However, the differences were not statistically significant and in fact could be expected given the span size and location of the defects.

The overall implant success rates within this study are consistent with published long-term results of implants placed in horizontally and vertically regenerated bone^{4,9} and with results reported for implants placed in native bone.²¹⁻²⁵ The overall cumulative implant survival rate of 100% and cumulative success rate of 94.7% in this study compare favorably with the aforementioned studies on implants placed in regenerated bone as well as native bone. However, there was a marked difference in results reported in previous studies on vertical GBR and the current study. Implant survival and implant success rates were 92% and 76%, respectively, in a study that combined sinus augmentation and posterior maxillary vertical ridge augmentation,¹⁰ whereas 100% implant success was achieved in a similar population in the current study (group C). However, in the previous report, only machined-surface implants were used, whereas enhanced-surface implants were used in the current study. The use of enhanced implant surfaces may have helped, especially in the posterior maxilla where the bone quality is typically poor. Also, in the previous report 7 patients (50%) were treated with a simultaneous technique, whereas in the current study the same type of patients were treated with a staged technique, which allowed more time for regenerated bone to mature prior to loading.

In the present report, the complication rate was 2.78%. This is significantly lower than the complication rates reported in earlier clinical studies on vertical augmentation with GBR (ranging from 12.5% to 17%),

and these earlier reports also included membrane exposures and/or subsequent infections.^{5,7,8,10} The technique employed in this vertical augmentation study is essentially the same technique reported previously.⁵ However, this retrospective study represents the time period when vertical ridge augmentation was considered routine clinical practice and does not represent the initial learning curve. The results of this study indicate that (1) there can be reduced complication rates with vertical bone regeneration, (2) implants can be placed successfully in vertically regenerated bone, and (3) implants can survive over time with high clinical success rates.

Some similarities and differences have been identified between the present study and the previously reported studies. These studies should be analyzed in a meta-analytic fashion to coalesce the data into a more meaningful finding relative to the current state of the science on vertical augmentation. Also, since most of the vertical augmentation studies reported in the literature have been retrospective in nature, future research should focus on long-term prospective studies.

CONCLUSIONS

Within the limitations of this retrospective study, the results suggest that the following conclusions can be made: (1) vertical augmentation with e-PTFE membranes and particulated autografts is safe and predictable, with minimal complications; (2) clinical success and survival of implants placed in vertically augmented bone with the GBR technique appear similar to success and survival of implants placed in native bone under loading conditions, regardless of the harvest site, surgical area, or defect size; and (3) the success and survival rates of implants placed simultaneously with sinus and vertical augmentation techniques compare favorably to those in sites requiring vertical augmentation of single- or multiple-tooth ridge defects. The results of this retrospective study should be verified with studies of more rigorous designs.

REFERENCES

1. Buser D, Brägger U, Lang NP, Nyman S. Regeneration and enlargement of jaw bone using guided tissue regeneration. *Clin Oral Implant Res* 1990;1:22-32.
2. Jovanovic SA, Spiekermann H, Richter EJ. Bone regeneration around titanium dental implants in dehiscence defect sites: A clinical study. *Int J Oral Maxillofac Implants* 1992;7:233-245.

3. Buser D, Dula K, Hirt HP, Schenk RK. Lateral ridge augmentation using autografts and barrier membranes: A clinical study with 40 partially edentulous patients. *J Oral Maxillofac Surg* 1996;54:420-432.
4. Buser D, Ingimarsson S, Dula K, Lussi A, Hirt HP, Belser UC. Long-term stability of osseointegrated implants in augmented bone: A 5-year prospective study in partially edentulous patients. *Int J Periodontics Restorative Dent* 2002;22:109-117.
5. Tinti C, Parma-Benfenati S. Vertical ridge augmentation: Surgical protocol and retrospective evaluation of 48 consecutively inserted implants. *Int J Periodontics Restorative Dent* 1998;18:434-443.
6. Jovanovic SA, Schenk RK, Orsini M, Kenney EB. Supracrestal bone formation around dental implants: An experimental dog study. *Int J Oral Maxillofac Implants* 1995;10:23-31.
7. Simion M, Trisi P, Piattelli A. Vertical ridge augmentation using a membrane technique associated with osseointegrated implants. *Int J Periodontics Restorative Dent* 1994;14:496-511.
8. Simion M, Jovanovic SA, Trisi P, Scarano A, Piattelli A. Vertical ridge augmentation around dental implants using a membrane technique and autogenous bone or allografts in humans. *Int J Periodontics Restorative Dent* 1998;18:18-23.
9. Simion M, Jovanovic SA, Tinti C, Parma-Benfenati S. Long-term evaluation of osseointegrated implants inserted at the time or after vertical ridge augmentation. A retrospective study on 123 implants with 1-5 year follow-up. *Clin Oral Implants Res* 2001;12:35-45.
10. Simion M, Fontana F, Rasperini G, Maiorana C. Long-term evaluation of osseointegrated implants placed in sites augmented with sinus floor elevation associated with vertical ridge augmentation: A retrospective study of 38 consecutive implants with 1- to 7-year follow-up. *Int J Periodontics Restorative Dent* 2004;24:208-221.
11. Jovanovic SA, Altman RR. Reconstruction of the posterior maxilla following total loss of crestal bone support. *Pract Periodontics Aesthet Dent* 1998;10:241-244.
12. van Steenberghe D, Lekholm U, Bolender C, et al. Applicability of osseointegrated oral implants in the rehabilitation of partial edentulism: A prospective multicenter study on 558 fixtures. *Int J Oral Maxillofac Implants* 1990;5:272-281.
13. Buser D, Weber HP, Lang NP. Tissue integration of non-submerged implants. 1-year results of a prospective study with 100 ITI hollow-cylinder and hollow-screw implants. *Clin Oral Implants Res* 1990;1:33-40.
14. Wyatt CC, Byant SR, Avivi-Arber L, Chaytor DV, Zarb GA. A computer-assisted measurement technique to assess bone proximal to oral implants on intraoral radiographs. *Clin Oral Implants Res* 2001;12:225-229.
15. Albrektsson T, Zarb G, Worthington P, Eriksson B. The long-term efficacy of currently used dental implants: A review and proposed criteria of success. *Int J Oral Maxillofac Implants* 1986;1:11-25.
16. Wennstrom JL, Palmer RM. Consensus report of Session C. In: Lang NP, Karring T, Lindhe J (eds). *Proceedings of the 3rd European Workshop on Periodontology: Implant Dentistry*. Berlin: Quintessenz, 1999:255-259.
17. Colton T. Longitudinal studies and the use of the life table. In: Colton T. *Statistics in Medicine*. Boston: Little, Brown and Company, 1974:237-250.
18. Hunt DR, Jovanovic SA. Autogenous bone harvesting: A chin graft technique for particulate and monocortical bone blocks. *Int J Periodontics Restorative Dent* 1999;19:165-173.
19. Nevins M, Mellonig JT, Clem DS III, Reiser GM, Buser DA. Implants in regenerated bone: Long-term survival. *Int J Periodontics Restorative Dent* 1998;18:34-45.
20. Zitzmann NU, Schärer P, Marinello CP. Long-term results of implants treated with guided bone regeneration: A 5-year prospective study. *Int J Oral Maxillofac Implants* 2001;16:355-366.
21. Lekholm U, van Steenberghe D, Herrmann I, et al. Osseointegrated implants in the treatment of partially edentulous jaws: A prospective 5-year multicenter study. *Int J Oral Maxillofac Implants* 1994;9:627-635.
22. Adell R, Lekholm U, Rockler B, Brånemark PI. A 15-year study of osseointegrated implants in the treatment of edentulous jaws. *Int J Oral Surg* 1981;10:387-416.
23. Adell R, Eriksson B, Lekholm U, Brånemark PI, Jemt T. Long-term follow-up study of osseointegrated implants in the treatment of totally edentulous jaws. *Int J Oral Maxillofac Surg* 1990;5:347-359.
24. Jemt T, Lekholm U. Oral implant treatment in posterior partially edentulous jaws: A 5-year follow-up report. *Int J Oral Maxillofac Implants* 1993;8:635-640.
25. Lekholm U, Gunne J, Henry P, et al. Survival of the Brånemark implant in partially edentulous jaws: A 10-year prospective multicenter study. *Int J Oral Maxillofac Implants* 1999;14:639-645.